



RESENTING CLINICAL SIGNS

History: Grade 1-2/6 murmur. Asymptomatic.

DATE

6/22/22

ECHOCARDIOGRAPHIC FINDINGS

2D, M-mode, and Doppler study.

PERFORMED BY:

Kelly Vazquez

INTERPRETED BY

Keith Blass, DVM,
MS, DACVIM
(Cardiology)

There is mild left atrial dilation. The mitral valve leaflets are thickened and exhibit mild systolic prolapse. A mild to moderate jet of eccentric mitral regurgitation is present. There is mild left ventricular dilation. Left ventricular systolic function is normal. The aorta and aortic valve appear normal, though trace aortic insufficiency is present. Right atrial and right ventricular dimensions are normal. The tricuspid valve leaflets are mildly thickened, and a mild jet of tricuspid regurgitation is present. The pulmonary artery and pulmonic valve appear normal, though trace pulmonic insufficiency is present. No pericardial effusion or cardiac masses are seen.

LA – 35.7 mm
LVIDd – 35.5 mm
LVIDs – 20.7 mm
FS – 41.7%

PATIENT

Blaze Haskins

RA – 20.0 mm
LVOT – 1.19 m/s
RVOT – 0.75 m/s

ASSESSMENT/RECOMMENDATIONS

SPECIES

Canine

Degenerative mitral and tricuspid valve disease

BREED

CKCS

This examination demonstrates regurgitation of blood across Blaze's mitral and tricuspid valves resulting from degenerative valve disease. Blaze's tricuspid valve disease is mild, and is well-compensated at this time. His mitral valve disease is a bit more advanced, as Blaze has mild to moderate mitral regurgitation present, with mild secondary dilation of both his left atrium and left ventricle, though his left ventricular systolic function is well-preserved. As only mild left heart chamber dilation is present, Blaze's current risk for the development of clinical signs secondary to his disease, such as coughing, exercise intolerance, syncope, and labored breathing, appears to be relatively low, though careful monitoring for these signs is recommended going forward.

SEX

MN

I recommend starting Blaze on pimobendan (5 mg am, 2.5 mg pm), as this medication should help to slow the progression of his mitral valve disease.

AGE

9 y

A recheck echocardiogram is recommended in 9 months. Thoracic radiographs are recommended if Blaze experiences respiratory clinical signs.

WEIGHT

29 lb

HOSPITAL NAME

Ho-Ho-Kus VH

REFERRING VET

Dr. Gannon



DATE

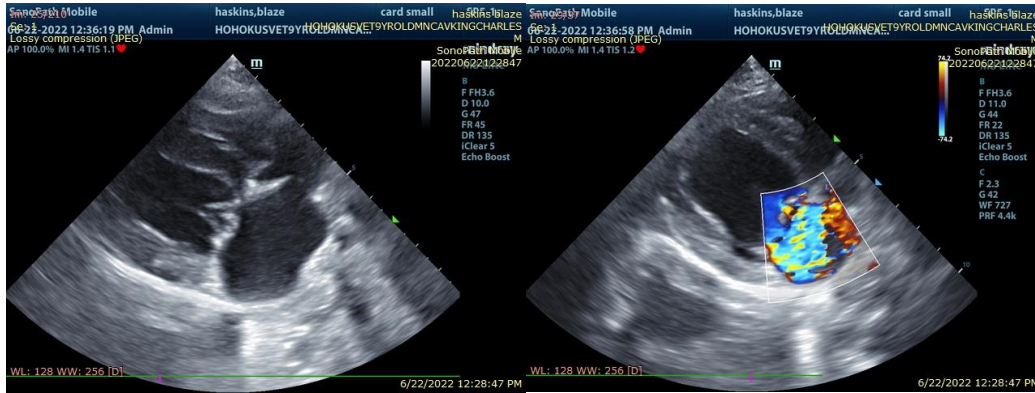
6/22/22

PERFORMED BY:

Kelly Vazquez

INTERPRETED BY

Keith Blass, DVM,
MS, DACVIM
(Cardiology)



The information and recommendations provided are based on the images presented by the referring veterinarian. No evaluation can be communicated regarding pathology that was not visible in the image/video clips provided.

PATIENT

Blaze Haskins

Thank you for this referral. If the clinical or image interpretation does not parallel your findings or if I can be of any further assistance please contact me.

Keith Blass, DVM, MS, DACVIM (Cardiology)
KeithBlass@gmail.com
631-804-5754

SPECIES

Canine

BREED

CKCS

SEX

MN

AGE

9 y

WEIGHT

29 lb

HOSPITAL NAME

Ho-Ho-Kus VH

REFERRING VET

Dr. Gannon